

Unusual Site for Fibro-lipoma – A Case Report

Amir Yousaf¹, Shawaz Abbas²

ABSTRACT

Lipomas and Sebaceous cysts are the most common lumps found in the subcutaneous area. Fibro-lipoma a rare benign tumor, is comprises of both fibrous connective tissues and adipose cells. Although it can be anywhere in the human body, where these tissues are present. But they are rare in the lower extremities. The differential diagnosis of lump in the foot may be challenging, especially when access to special imaging tools is limited in some practice. We are reporting a solitary large fibro-lipoma on the dorsal aspect of the foot in a middle-aged male patient.

Keywords: Lipoma, fibrous, adipose, dorsal

This is an Open Access article distributed under the terms of the Creative Commons Attribution-Noncommercial 4.0 International License (<http://creativecommons.org/licenses/by-nc/4.0/>), which permits unrestricted use, distribution, and reproduction in any medium, provided the original work is properly cited.

INTRODUCTION

Lumps can be on or underneath the skin. They are different types of lumps, which includes skin tags, cysts, warts, lymphoma or melanoma. Lipomas are non-cancerous fatty tumours composed of adipocytes, which are mostly asymptomatic. If they are small then they are left alone otherwise they can be removed, simply by operation under local anaesthesia for symptomatic or cosmetic reasons. Lipomas are labelled as fibro-lipoma when fibrous septa are present along with mature fat cells¹. They are usually found in the subdermal level, but sometimes they may be located in a subfascially^{2,3}. These lumps according to their precise location are further classified as parosteal, interosseous, visceral, intra and intermuscular^{4,5}. Fibro-lipoma can present in upper half of the body, but seldom seen in anterior abdominal wall. Their presence in the extremities, particularly the lower limbs are also rare¹. We are presenting a case of a solitary fibro-lipoma on the dorsal surface of the right foot which is a rare site for this pathology.

CASE REPORT

A fifty – two years old male patient, business man by profession

1. Consultant Surgeon
2. Medical Officer

Government Mian Meer Hospital, Lahore

Correspondence:

Amir Yousaf
 Consultant Surgeon,
 Government Mian Meer Hospital, Lahore
 Email: yousafamir@hotmail.com

Received for Publication: July 21, 2022

1st Revision of Manuscript: August 29, 2022

2nd Revision of Manuscript: September 19, 2022

Accepted for Publication: October 17, 2022

and a known case of hypertension, taking regular medication, presented in surgical out - patient department, with a painless lump on the dorsal surface of second toe of the right foot for the last six to seven years. According to the patient initially the swelling was small, but later the size increase without any pain. Clinically the lump dimension was 3.5 x 3.0 cm, hemispherical, smooth surface without any inflammatory changes as well as regional lymphadenopathy. The consistency of the lump was soft with clearly defined edges and the skin above it was mobile. The trans-illumination test was negative and the patient was denying any neurological symptoms like numbness. Cosmetically the swelling was not acceptable to the patient and he was unable to wear dress shoes (Figure 1A, B). A provisional diagnosis of lipoma, neurofibroma and liposarcoma was made. Plain radio-graphs of the foot showed soft tissue shadows with any bony involvement. Due to non-availability, MRI was not done. The patient was planned for elective excision under local anaesthesia.

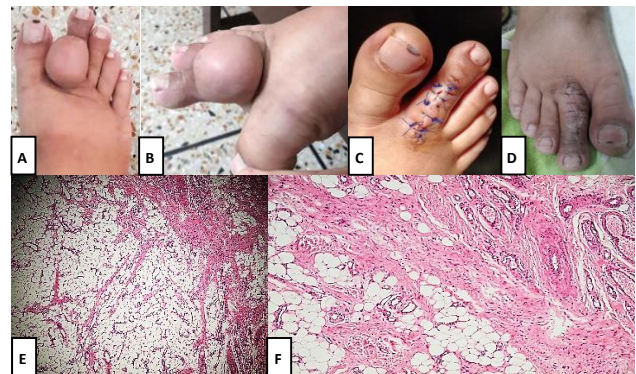


Figure – 1: The clinical dimension of the lump from side and front (A, B). Post operative in the recovery area and review in the follow up (C, D). The histopathology slides (E, F) with adipose tissue and fibrous septa.

The lump was excised under local anaesthesia as a day case surgery. The lump was carefully dissected from the underlying fascia, tendon, bone and surrounding structures. The capillary refilling test

was performed on the operated toe after 10 to 15 minutes, to see the integrity of distal circulation. The patient was followed up to review the wound and toe. The specimen was sent for histopathology, which showed a benign encapsulated adipocytic neoplasm comprised of mature adipocytes with foci of fibrous tissue septa, with no evidence of malignancy (Figure 1E, F).

DISCUSSION

According to World Health Organization (WHO), lipomas are classified into classic lipoma, lipomatosis, pleomorphic lipoma, lipoblastoma, angioliipoma, angiomyolipoma, myelolipoma, hibernoma and atypical lipoma⁶. Fibro-lipoma is not included in this classification due rare variant present in a classic lipoma. The main component due to which it is labelled is the presence of fibrous connective tissue¹. Fibro-lipomas are not uncommon in the fifth or sixth decade of patient's life. Although the aetiology is unknown, but mechanical, hormonal and inflammatory factors do have association in their occurrence⁷. Any part of the human body containing adipose and fibrous tissue can develop fibro-lipoma, but they are more commonly seen in the trunk, upper limbs and neck area^{1,8}. However presence of fibro-lipoma in the lower extremities is rare⁹, which is treacherous very slow growing non-tender lump with smooth surface. They are considered as giant lipomas, when they weigh more than thousand grams or they are more than ten centimeters in dimension¹⁰. Due to the lack of expansion in the skin at the peripheries of the extremities, patients can experience compression syndrome. Therefore, it is said that the location of the lump is more important than its size.

The diagnosis of Fibro-lipoma can be made by ultrasonography, as the mature fats tissue can show itself engraved in a fibrous capsule¹¹. Giant lipomas need to be differentiated from malignant lumps like liposarcomas, histiocytomas, epidermoid cysts, hemangiomas and lipo-blastomatosis. However, when there is any suspicious of bone involvement then computerized tomography CT scan can be a good choice to make the diagnosis. The sinister pathologies like liposarcoma can further be differentiated with contrast enhancement in the late phase as it shows increase uptake. On the other hand, MRI can correctly diagnose lump of the foot in 89% of the cases. It will show hyper intense and hypo intense masses separated with linear areas of decrease signal intensity, but it cannot discriminate well between well differentiated liposarcoma and simple lipoma^{12,13}, therefore a core biopsy may be required preoperatively to distinguish lipoma from well differentiated liposarcoma. In our patient the differential diagnosis was neurofibroma and liposarcoma. A neurofibroma is not very much mobile, has a firm consistency and the trans illumination test is negative, however a liposarcoma has a short history as compared to neurofibroma, firm in consistency and maybe attached to the surrounding structures. The reoccurrence of the lump depends upon the surgical skills. If a giant fibro-lipoma has removed incompletely then there is a higher rate of reoccurrence, whereas small masses reoccur rarely.

CONCLUSION

Fibro-lipomas of the lower extremities or feet are rare. They should be considered in the differential diagnosis of soft tissue masses of the foot apart from other soft tissue and bony sinister pathology. Due to inconclusive or non-availability of the imaging investigations, it is important to recognize the clinical signs of such swelling in an unusual site. The complete resection should be emphasized, which is the key factor to avoid recurrence along with histopathology result so that the lump can be differentiated from any other sinister pathology.

AUTHOR'S CONTRIBUTION

Yousaf A: Conceived idea, Manuscript Writing, Manuscript final reading

Abbas S: Data Collection

Disclaimer: None.

Conflict of Interest: None.

Source of Funding: None.

REFERENCES

- Balakrishnan C, Nanavati D, Balakrishnan A. Giant lipomas of the upper extremity: case reports and a literature review. *Can J Plast Surg* 2012; 20:40–41
- Cribb GL, Cool WP, Ford DJ. Giant lipomatous tumours of the hand and forearm. *J Hand Surg Br* 2005; 30:509–512.
- Sanchez MR, Golomb FM, Moy JA. Giant lipoma: case report and review of the literature. *J Am Acad Dermatol* 1993; 28:266–268
- Fletcher CD, Martin-Bates E. Intramuscular and intermuscular lipoma: neglected diagnoses. *Histopathology* 1988; 12:275–287.
- Billing V, Mertens F, Domanski HA. Deep-Seated ordinary and atypical lipomas: histopathology, cytogenetics, clinical features, and outcome in 215 tumours of the extremity and trunk wall. *J Bone Joint Surg Br* 2008; 90:929–933
- Weiss SW, Sobin LH, Enzinger FM. Lipomatous tumours. In: *Histological typing of soft tissue tumours (World Health organization international histological classification of tumours). Pathologists in 9 countries*, eds. 23. 2nd ed. Springer-Verlag, 1994;Pp231-267.
- Rao GS, Chatra L, Shenai P. Intra oral Lipoma-A rare entity. *Int J Anat Radiol Surg* 2013; 2:1–3
- Vandeweyer E, Scagnol I. Axillary giant lipoma: a case report. *Acta Chir Belg* 2005; 105:656–657
- Lui TH. Fibrolipoma of the toe. *Foot Ankle Spec* 2010; 3:33–34
- Zografos GC, Kouerinis I, Kalliopi P. Giant lipoma of the thigh in a patient with morbid obesity. *Plast Reconstr Surg* 2002; 109:1467–1468
- Whittle C, Cortés M, Baldassare G. [Subgaleal lipomas: ultrasound findings]. *Rev Med Chil* 2008; 136:334–337
- Wetzel LH, Levine E. Soft-tissue tumors of the foot: value of MR imaging for specific diagnosis. *AJR Am J Roentgenol* 1990; 155: 1025–1030.
- O'Donnel PW, Griffin AM, Eward WC. Can experienced observers differentiate between lipoma and well-differentiated liposarcoma using only MRI? *Sarcoma* 2013; 2013: 982784 (6 pp.).